

# Vaginal Closure Before Colpotomy with an Endo-Stapler to Prevent Tumor Spillage in Laparoscopic Surgery for Gynecological Malignancy

Dipak Limbachiya, MD, Rashmi Kumari, MS

## ABSTRACT

**Background and Objectives:** The aim of this study was to define new techniques for performing vaginal closure with endo-staplers to prevent tumor spillage during laparoscopic surgeries for endometrial cancer and early stage cervical cancer.

**Methods:** Thirteen patients were retrospectively studied for the use of endo-staplers for vaginal closure before colpotomy during laparoscopic surgeries for endometrial cancer and early stage cervical cancer to prevent tumor spillage.

**Results:** There were no short-term or any long-term complication related to the use of the endo-staplers for colpotomy in the surgeries included in this study.

**Conclusion:** Use of the endo-staplers to close the vagina before colpotomy according to the technique described is safe and feasible, with prevention of gross spillage of any malignant cells in the peritoneal cavity or vagina, which will further have a favorable oncologic outcome.

**Key Words:** Laparoscopic surgeries, Gynecological malignancies, Vaginal closure, Endo-staplers, Intracorporeal colpotomy.

## INTRODUCTION

Minimally invasive surgery (MIS) for gynecological malignancies has emerged as a possible substitute that offers significant advantages over laparotomy procedures without compromising the surgical and oncologic outcomes.<sup>1,2</sup> This proposition is reinforced in several recent articles which approvingly illuminate the role of MIS in gynecological malignancies.<sup>3,4</sup> However, there some studies have doubted the effectiveness of MIS for gynecological malignancies, as it was found to be associated with lower rates of disease-free survival and shorter overall survival than an open abdominal approach.<sup>5,6</sup> This might be due to various probabilities, but one of the most potential components being reviewed and frequently debated is intracorporeal colpotomy.

Intracorporeal open colpotomy could possibly predispose the risk of tumor spillage and metastasizing the malignant cells into the peritoneal cavity and vagina. Kong et al.<sup>7</sup> compared the pattern of recurrence and survival in patients with early cervical cancer who underwent laparoscopic/robotic radical hysterectomy with vaginal colpotomy and those who underwent intracorporeal colpotomy. The study concluded that disease recurrence was higher in the intracorporeal colpotomy group than in the vaginal colpotomy group (16.3% vs. 5.1%), and among patients with recurrence in the intracorporeal group, 62.5% had intraperitoneal spread.

The aim of this study was to define new techniques for performing vaginal closure with endo-staplers during laparoscopic surgeries for endometrial cancer and early stage cervical cancer to prevent tumor spillage. Advantages and disadvantages of these techniques are also discussed. The technique was evaluated for its feasibility, replicability, operating time, or any complication intra-operatively and postoperatively related to the use of the endo-staplers for vaginal closure. The length of hospital stay of all the patients were also assessed.

## MATERIALS, METHODS, AND SURGICAL TECHNIQUE

This is a retrospective analysis. Inclusion criterion for this study were:

- Endometrial cancer (International Federation of Gynecology and Obstetrics [FIGO] Stage I–III)

Department of Gynecological Endoscopy, Eva Women's Hospital, Ahmedabad, India (Drs. Limbachiya and Kumari).

IRB/Ethics Committee: approved this study.

Disclosure statement: none.

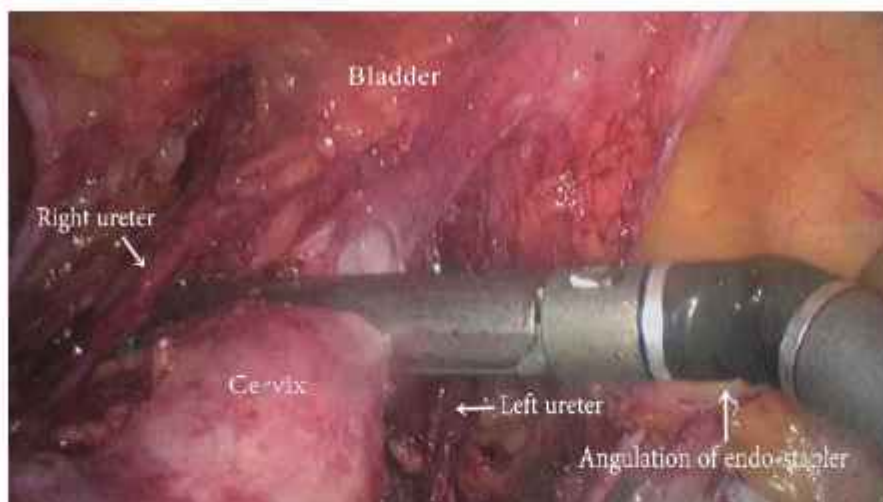
Informed consent: Dr. Dipak Limbachiya declares that written informed consent was obtained from the patient/s for publication of this study/report and any accompanying images.

Funding: none.

Address correspondence to: Dr. Dipak Limbachiya, Department of Gynecological Endoscopy, Eva Women's Hospital, Neelkanth Park 2, Ghoda Camp Road, Shahibaug, Ahmedabad, Gujarat, India 380004, Telephone: +91-9825028771, E-mail: limbachiyaadipk63@gmail.com.

DOI: 10.4293/JSLS.2020.00094

© 2021 by SLS, Society of Laparoscopic & Robotic Surgeons. Published by the Society of Laparoscopic & Robotic Surgeons.



**Figure 1.** Endo-view showing angulation and proper placement of endo-stapler.

#### b. Early stage cervical cancer of (FIGO Stage IA2, IB1, and IB2)

All surgeries (13) were performed in our center between March 1, 2020 and September 30, 2020 by the same operating surgeon. There were eight cases of endometrial carcinoma and five cases of early stage carcinoma cervix. An informed written consent was taken from all the patients regarding the procedure.

### Surgical Technique

Under general anesthesia, the patient is placed in modified Lloyd Davis position at 30° angle with the horizontal. The operating surgeon stood on the left side of the patient. The first assistant holding the camera was positioned towards the head end of the table; the second assistant on the right side helps with uterine manipulation, grasping and retracting tissues. Port positions: five trocars were used in the authors' technique. The primary trocar (10 mm) was inserted at 1 cm above the umbilicus. Four accessory trocars (5 mm) were inserted under direct vision, two on the left and two on the right side. Abdomen was insufflated with CO<sub>2</sub> gas and maintained at a pressure of 12 mm Hg during the surgery.

Laparoscopic surgery for endometrial cancer and early stage cervical cancer was completed as per the standard technique following the oncologic principles till colpotomy. The maneuvers used during surgery to prevent tumor spillage:

- Vaginal packing with a Povidone-Iodine solution soaked mop
- No use of uterine manipulator

- Blocking of bilateral fallopian tubes with hemo-clips at the initiation of surgery
- Completion of surgery with bipolar and scissor
- Use of endo-staplers for vaginal closure before colpotomy
- The vaginal closure was done according to the technique described below.

### Steps

Before proceeding with colpotomy, vaginal closure is done with endo-staplers to prevent tumor spillage into the peritoneal cavity and vagina. The detailed technical steps are hereby described.

#### 1) Skeletonization of Para-Vaginal Tissue

The site of vagina at which stapler is to be applied is cleared off its paracolpos tissue for the proper placement of endo-stapler.

#### 2) Conversion of 5-mm to 12-mm Port

The initial 5-mm right lower quadrant trocar was changed to a 12-mm trocar to allow for the placement of an endo-stapler system with a green cartridge (60 mm in length).

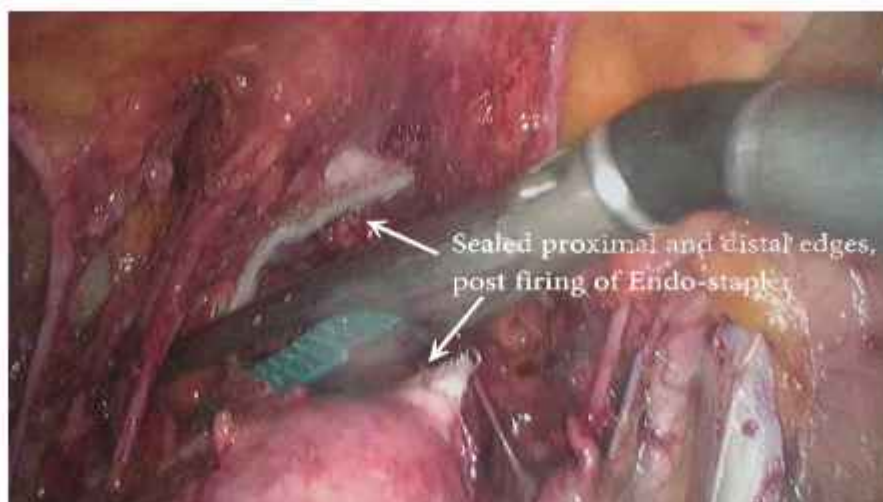
#### 3) Introduction of Endo-Stapler

Endo-stapler was introduced through the right lower 12 mm port under vision.

#### 4) Angulation of Endo-Stapler (Figure 1)

Endo-stapler was angulated on its long axis for about 90° turn for the proper transverse placement of two blades of the endo-stapler over the anterior and posterior wall of vagina.





**Figure 2.** Endo-view showing sealed proximal and distal edges post firing of endo-stapler.

#### **5) Placement of Endo-Stapler (Figure 1)**

Further the stapler was positioned. Anteriorly urinary bladder, posteriorly rectum and laterally bilateral ureters were kept away from the two jaws of the stapler before the firing.

#### **6) Firing of Endo-Stapler (Figure 2)**

The surgical endo-stapler was fired one time to close the vagina. The stapler places three triple-staggered rows of titanium alloy staples on either side of the cut line and the built-in knife blade in endo-stapler cuts simultaneously between them. Once the vagina was divided, the stapler was released.

#### **7) Withdrawal of Endo-Stapler**

Again the angulated proximal end of endo-stapler was straightened and withdrawn from the right lower port under vision.

#### **8) Opening of Vagina (Figure 3)**

The upper part of the vaginal cuff which was sealed with endo-stapler was excised with cold scissors and sent for pathological examination as extra-surgical margin. The average length of vagina excised was 2.5 – 3 cm.

#### **9) Final Step-Delivery of the Specimen**

The main specimen of uterus with cervix with its sealed vaginal end was removed through the freshly unsealed vagina in endobag.

#### **10) Closure of Vagina**

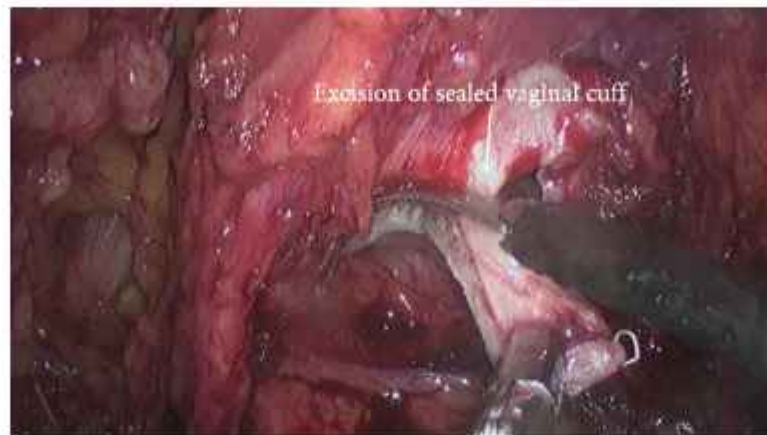
Finally, the opened end of vaginal cuff was closed with intracorporeal suturing.

## **RESULTS**

A total of 13 patients underwent operations for gynecological malignancies (endometrial cancer and early stage cervical cancer) between March 1, 2020 and September 30, 2020 with vaginal closure done as mentioned above. The median age of the patients was 56 years (range, 43 – 80 years) and the median body mass index was 25.4 kg/m<sup>2</sup> (range, 22.2 – 32 kg/m<sup>2</sup>). There was no significant increase in the duration of surgery following this technique of vaginal closure before colpotomy compared with our conventional method of colpotomy in laparoscopic gynecological surgery. None of the cases were converted to laparotomy. The median hospital stay was 2 days (range 1 – 3 days). At the writing of this article, there have been no short-term or any long-term complications related to the use of the endo-staplers for colpotomy in these performed surgeries.

## **DISCUSSION**

MIS was introduced as an aid to substantiate the diagnosis of cancer. Since then, owing to continued enhancement of surgical skills and technological advancement it has become a complete therapeutic treatment, contributing to staging of the malignancy, delineate the requirement of adjuvant therapy, and managing locoregional recurrence. MIS represents an alternative standard of care to open



**Figure 3.** Endo-view showing excision of sealed vaginal cuff with cold scissor.

abdominal procedures for patients with endometrial and early-stage cervical cancers with fewer peri-operative and postoperative complications, preferable postoperative quality of life, shorter hospital stay, and faster recovery. Furthermore, MIS may be especially beneficial for obese or elderly patients with numerous comorbidities. Its efficacy and favorable oncologic outcomes have been well documented in various studies.<sup>1-4</sup> Nezhat et al. in 2020, also documented a comparable conclusion regarding the role of MIS on reproductive and oncologic outcomes after fertility sparing surgery for early stage cervical cancer.<sup>3</sup> However, minimally invasive procedures have not been completely generalizable owing to some recent studies which have doubted the oncologic safety of these methods. It was reported that minimally invasive radical hysterectomy was associated with inferior prognosis than that of the open abdominal counterpart.<sup>5,6</sup> But this can be a premature assertion, as Nezhat et al. in 2019 also advocated for a similar perspective that averaged reporting without considering the variations in surgical proficiency that could result in unforeseen adverse consequences.<sup>4</sup> There might be various suspects for inferior outcome of MIS over laparotomy procedures, but intracorporeal open colpotomy can be a significant factor responsible for seeding the viable malignant cells into the peritoneal cavity and vagina and thus lead to adverse oncologic outcomes.

Intracorporeal open colpotomy, which is the last step of minimally invasive surgery for gynecological malignancies (endometrial cancer and early stage cervical cancer), may increase the risk for tumor spillage.<sup>7</sup> Canis et al. in 2001 concluded that the risk of dissemination of cancer cells following laparoscopic management of gynecologic cancers is primarily associated with laparoscopic tissue

manipulations, intra-operative rupture, or unprotected removal of a surgical specimen.<sup>8</sup> Therefore, closure of the upper vagina before colpotomy may avoid this risk of tumor diffusion into the peritoneal cavity. This study is in accordance with the Boyraz et al.<sup>9</sup> study where vaginal closure was done with a surgical stapler to prevent tumor spillage in laparoscopic radical hysterectomy. Yuan P et al.<sup>10</sup> ligated the upper vagina with a suture before colpotomy and then proceeded for the same. However, a suture ligation cannot be tight enough to be impermeable to tumor tissue. Moreover, the sealing effect of suture is subject to individual strength variation and there are chances of slippage of ligature also. While endo-staplers provide a uniform watertight closure without any percolation of tissue through the stapler line and can offer better oncologic outcomes. This technique to seal the upper vagina before colpotomy is easy, simple, and replicable.

This study has some limitations, which are innate to any retrospective study. In addition, the cost of endo-staplers used for colpotomy might be a limiting factor in some settings, but for a better oncologic outcome this can be afforded. Moreover, further long term follow-up is required to authenticate this hypothesis. To our knowledge this is the first study with substantial sample size to use endo-staplers for vaginal closure before colpotomy in laparoscopic surgeries for endometrial cancer and early stage cervical cancer to prevent tumor spillage.

## CONCLUSION

Use of the endo-staplers to close the vagina before colpotomy according to the technique described is safe and



feasible. It provides adequate vaginal resection with grossly no spillage of any malignant cells in the peritoneal cavity or vagina. This technique will also improve the oncologic outcomes among women with early-stage cervical cancer and endometrial cancer, but further larger prospective studies are required to validate our hypothesis. A long term follow up is also required to substantiate this proposition.

## References:

1. Limbachiya D, Gandhi P, Kenkre M, et al. Laparoscopic radical hysterectomy with lymphadenectomy in cervical cancer: our technique and experience. *Eur J Gynecol Oncol*. 2019;40:394–401.
2. Limbachiya D. Surgicopathological outcomes and survival in carcinoma body uterus: a retrospective analysis of cases managed by laparoscopic staging surgery in Indian women. *Gynecol Minim Invasive Ther*. 2020;9(3):139–144.
3. Nezhat C, Roman RA, Rambhatla A, Nezhat F. Reproductive and oncologic outcomes after fertility-sparing surgery for early stage cervical cancer: a systematic review. *Fertil Steril*. 2020;113(4):685–703.
4. Nezhat FR, Ananth CV, Vintzileos AM. Two Achilles heels of surgical randomized controlled trials: differences in surgical skills and reporting of average performance. *Am J Obstet Gynecol*. 2019;221(3):230–232.
5. Melamed A, Margul DJ, Chen L, et al. Survival after minimally invasive radical hysterectomy for early-stage cervical cancer. *N Engl J Med*. 2018;379(20):1905–1914.
6. Ramirez PT, Frumovitz M, Pareja R, et al. Minimally invasive versus abdominal radical hysterectomy for cervical cancer. *N Engl J Med*. 2018;379(20):1895–1904.
7. Kong TW, Chang SJ, Piao X, et al. Patterns of recurrence and survival after abdominal versus laparoscopic/robotic radical hysterectomy in patients with early cervical cancer. *J Obstet Gynaecol Res*. 2016;42(1):77–86.
8. Canis M, Mage G, Botchorishvili R, et al. Laparoscopy and gynecologic cancer: is it still necessary to debate or only convince the incredulous? *Gynecol Obstet Fertil*. 2001;29(12):913–918.
9. Boyraz G, Karalok A, Basaran D, Turan T. Vaginal closure with EndoGIA to prevent tumor spillage in laparoscopic radical hysterectomy for cervical cancer. *J Minim Invasive Gynecol*. 2019;26(4):602.
10. Yuan P, Liu Z, Qi J, Yang X, Hu T, Tan H. Laparoscopic Radical Hysterectomy with Enclosed Colpotomy and without the Use of Uterine Manipulator for Early-Stage Cervical Cancer. *J Minim Invasive Gynecol*. 2019;26(6):1193–1198.