

# Laparoscopic radical hysterectomy with lymphadenectomy in cervical cancer: our technique and experience

**D. Limbachiya<sup>1</sup>, P. Gandhi<sup>2</sup>, M. Kenkre<sup>1</sup>, S. Shah<sup>1</sup>, H. Chawla<sup>1</sup>, G. Agrawal<sup>1</sup>, S. Sonara<sup>1</sup>**

<sup>1</sup>Advanced Endoscopy and Oncology Centre, EVA Women Hospital, Ahmedabad, Gujarat (India); <sup>2</sup>Department of Gynaecology, Scunthorpe General Hospital, Northern Lincolnshire and Goole Hospitals NHS Foundation Trust, Scunthorpe (United Kingdom)

## Summary

**Objective:** To describe our technique of total laparoscopic radical hysterectomy (LRH) in cervical cancer and share our experience. **Materials and Methods:** Retrospective study of 53 non-consecutive patients with International Federation of Gynaecology and Obstetrics (FIGO) Stage IA2 (n=1), IB1 (n=26), and IB2 (n=26) cervical cancer. All patients underwent total LRH with bilateral pelvic lymphadenectomy. Harmonic shears were the primary instrument used for the dissection, transection, and maintenance of hemostasis. Hemostasis was also achieved using bipolar graspers if deemed necessary. This study was approved by the local institutional review board (Sangini Hospital Ethics Committee), IRB registration number IRB00008709. **Results:** The median age was 47 (range, 28-70) years, with a median body mass index of 25.7 (range, 16-32) kg/m<sup>2</sup>. The median operative time was 103 (range, 61-150) minutes. There were no intraoperative complications. Median blood loss was 30 (range 20-135) mL. None of the cases required conversion to laparotomy. Postoperative complication rate was seen in 18 (34%) patients. Urinary dysfunction was the most common postoperative complication seen in 13 (24.5%) patients. The median number of pelvic nodes resected was 20 (range, 8-55). The surgical margins were free of disease in all cases. The median length of stay was four (range, 2-8) days. Thirty-five patients required adjuvant therapy post surgery. The median follow-up in this study was 38 (range 0-97) months. Recurrence of the disease was seen in three patients. Four patients expired. The estimated three-year overall survival rate was 92.6% in patients with disease  $\leq$  IB1 and 92.3% in those  $>$  IB1. **Conclusion:** The present technique of LRH is safe, feasible, and associated with less morbidity. It is associated with minimal intraoperative complications, blood loss, shorter operative time, and outcomes comparable to other studies. The present technique consists of simple steps, which are easily reproducible and replicable once the learning curve has been surpassed.

**Key words:** Laparoscopic radical hysterectomy; Cervical cancer; Pelvic lymphadenectomy.

## Introduction

With the development of laparoscopy, laparoscopic radical hysterectomy (LRH) has evolved in gynecological oncology as an alternative that offers the advantages of minimally invasive surgery without compromising the surgical and oncologic outcomes. The combined surgical technique of radical laparoscopic hysterectomy and pelvic lymphadenectomy for the treatment of patients with cervical cancer was described in the early 1990s by Canis *et al.* [1] and Nezhat *et al.* [2]. Laparoscopy has come a long way from being questionable for its radicality in the treatment of malignancies to now being the gold standard of approach in the hands of experts [3, 4], having survival outcomes similar to open approach and many studies supporting its feasibility [5].

We present our experience of 53 patients with cervical cancer Stages IA2-IB2, who underwent LRH by our technique.

## Materials and Methods

This is a retrospective study. Medical records of all the patients who underwent LRH for early cervical cancer at the present centre between February 2009 and June 2017 were reviewed. There were 53 patients diagnosed with cervical cancer of International Federation of Gynaecology and Obstetrics (FIGO) Stage IA2 (n=1), IB1 (n=26), and IB2 (n=26), who underwent LRH with bilateral lymphadenectomy during this period. This study had institutional review board approval from Sangini Hospital Ethics Committee.

Data was collected by reviewing the notes respectively and entered on to the computerized database (confidential). The demographic data, clinical characteristics, histopathology findings, surgical variables (operative time, estimated blood loss), oncologic outcomes, and intraoperative and postoperative complications were reviewed.

The operative time was measured from the first skin incision to the final skin suture. The estimated blood loss was calculated as the difference between the volume of liquid introduced into the pelvic cavity for irrigation purposes and the volume of liquid aspirated during the operation at the end of the surgery. If any swabs were used, they were weighed postoperatively and the difference between the preoperative and postoperative weight was added to

the estimated blood loss. Intraoperative complications were defined as an injury to the bowel, bladder, ureters, or blood vessels. Hospital stay was counted from the day of admission to the day of discharge with any fractional day being counted as a full day. Early postoperative complications were defined as those that occurred within 30 days of surgery. Overall survival was defined as the time from surgery to death from any cause.

The present authors' protocol was as follows: once the patient was referred to our hospital. Detailed history and physical examination was conducted. Pelvic examination (per speculum, vaginal examination, and per rectal examination) was performed in all the patients to check vaginal fornices and exclude parametrial involvement in all the patients referred with suspected cervical cancer. The diagnosis of cervical cancer was confirmed by cervical biopsy. Baseline laboratory investigations, chest radiograph, and computed tomography or magnetic resonance imaging of the abdomen and pelvis were conducted. Patients with Stage >1B1 underwent examination under anesthesia with cystoscopy to rule out bladder/parametrial involvement. The cancer was assigned the stage, based on the clinical staging set forth by FIGO-2009. Informed consent was obtained from all the patients after, thorough counseling detailing therapeutic options, risks, and benefits of the procedure.

Inclusion criteria were: (1) cervical cancer clinical Stage IA2, IB1, and IB2, (2) no evidence of nodal enlargement in imaging studies, (3) good performance status, and (4) surgery as primary therapeutic modality.

Exclusion criteria were: (1) those who received neoadjuvant therapy, (2) those diagnosed based on a post hysterectomy pathology report, (3) recurrent disease, (4) those with poor performance status, (5) Stump carcinoma, and (6) concomitant malignancies of the female genital system. The procedure was carried out in a single centre by the same surgeon.

LRH (type C1) was performed for the patients from 2015 onwards according to Querleu and Morrow classification (6), prior to 2015 type C2 LRH was performed. Systematic pelvic lymphadenectomy up to level 2 was performed in all cases.

### *Surgical technique*

All patients were operated under general anesthesia. The bladder was catheterized using Foley catheter. The patient was positioned in a modified Lloyd Davis position with 35-40 degree Trendelenburg's tilt. The surgeon stood on the left side of the patient. The first assistant holding the camera was positioned towards the head end of the table and the second assistant on the right side helps with uterine manipulation, grasping and retracting tissues. The third assistant was positioned at the vaginal end. Port positions: five trocars were used in the authors' technique. The primary trocar (10 mm) was inserted at 1 cm above the umbilicus. Four accessory trocars (5 mm) were inserted under direct vision, two on the left and two on the right side. The first port on the left side was inserted at 2 cm above and medial to the iliac crest and the second port was inserted midway between the supra-umbilical and the left lower quadrant port. Similarly, two trocars were placed on the right side as a mirror image to the left side (Figure 1).

#### *Step 1: Bladder dissection*

In the authors' technique, bladder dissection was the first step (Figure 2). The advantage of beginning with bladder separation was to assess the feasibility of the surgery. In cases of carcinoma

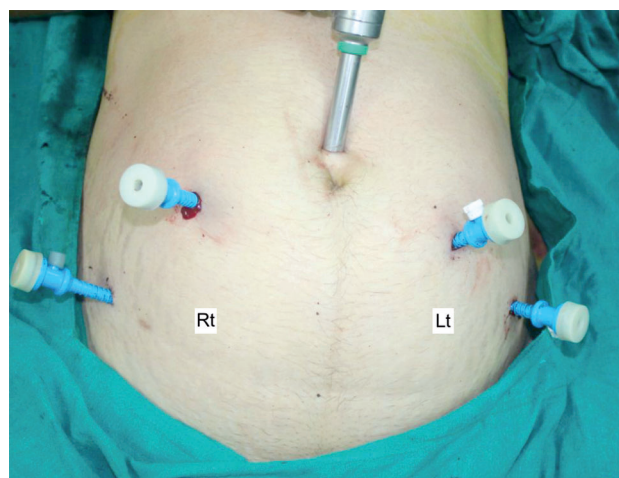


Figure 1. — Ports' position.

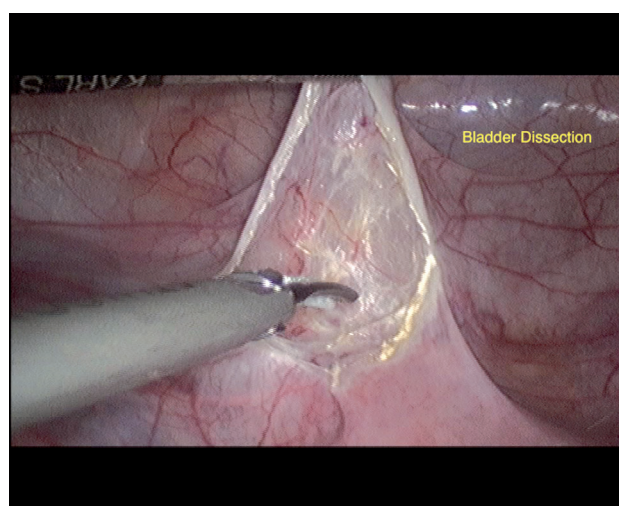


Figure 2. — Bladder dissection.

cervix where cancer infiltrates the bladder, it cannot be separated and makes it unsuitable for the surgery. Myoma screw was applied at the fundus to manipulate the uterus. The uterovesical fold was held in the mid-position and incised with harmonic shears. The incision was extended laterally to open the anterior leaf of the broad ligament on the right side up to the round ligament. Similarly, the anterior leaf of broad ligament was opened on the left side. The uterus was pulled cephalad and was retroverted to expose the uterovesical pouch adequately. The bladder was dissected using the harmonic shears. The carbon dioxide bubbles help in identification of the fascial plane between the bladder and the cervix. The dissection continues in the vesicovaginal plane until the bladder is mobilized away from the vagina to provide an adequate length of vaginal margins for excision.

#### *Step 2: Opening of the para-vesical space*

The loose connective tissue lateral to the bladder pillar was cut with harmonic shears. Dissection continued deep down medial and parallel to the obliterated hypogastric artery until the levator ani muscle was reached. The paravesical space was opened on the



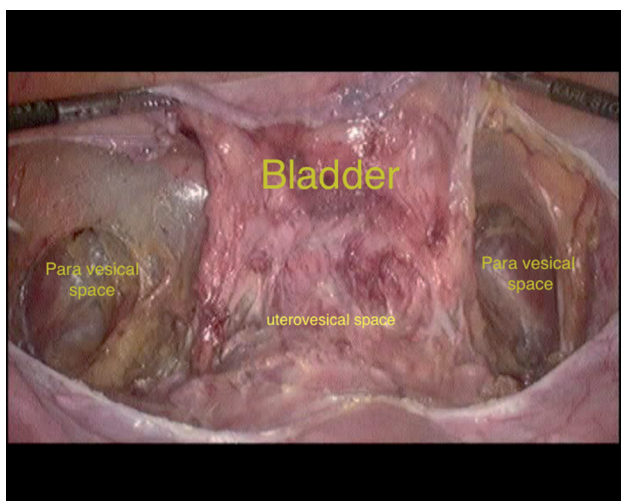


Figure 3. — Paravesical space.

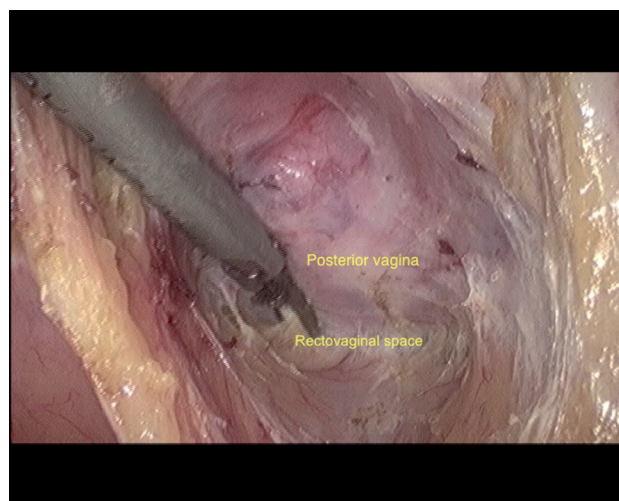


Figure 5. — Rectovaginal space.

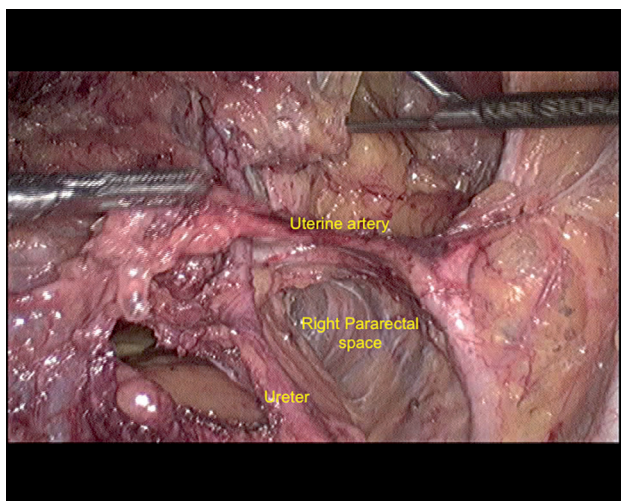


Figure 4. — Pararectal space.

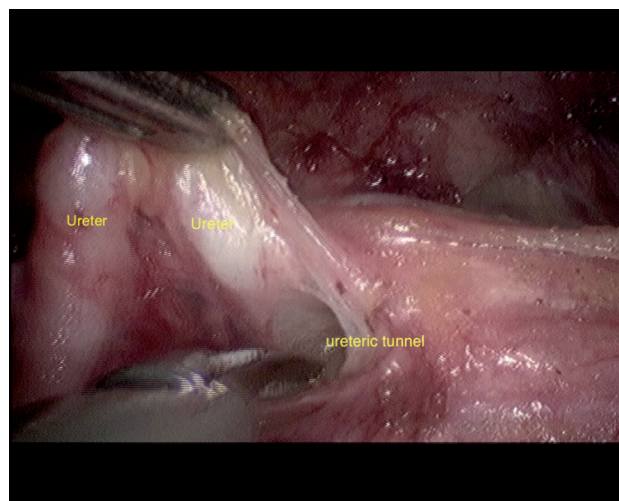


Figure 6. — Ureteric tunnel.

right side. Similar dissection was undertaken on the left side to open the left paravesical space (Figure 3).

#### *Step 3: Opening of the para-rectal space*

The retro-peritoneum dissection began from the round ligament. The left round ligament was cut using Harmonic shears, and the parietal peritoneum was opened parallel and lateral to the infundibulopelvic ligament. The first lateral structure seen was the external iliac artery, and the ureter was identified by its peristaltic movements. Dissection was performed lateral and parallel to the ureter until the uterine artery was identified at its origin from the internal iliac artery. The pararectal space was developed by dissecting the areolar tissue between the ureter and internal iliac artery, inferior to the origin of the uterine artery (Figure 4). The medial aspect of the pararectal space, also called Okabayashi's space, was created between the ureter and medial leaf of the broad ligament peritoneum, and the dissection continued deep down to into Okabayashi's space. Opening this space was vital to isolate

the inferior hypogastric nerve.

#### *Step 4: Dissection of recto-vaginal space*

The uterus was acutely anteverted, and the peritoneum between the two-uterosacral ligaments was incised with harmonic shears. The posterior peritoneum along with the adipose tissue of the rectum was held with the grasper and pushed down. This facilitated the identification of loose areolar plane between the two layers of Denonvilliers fascia. Dissection was continued in this plane staying above the adipose tissue of the rectum and below the posterior vaginal wall (Figure 5). Uterosacral and Mackenrodt ligaments were transected using harmonic shears. Similar steps were repeated on the left side. Opening all six avascular spaces delineated the parametrium and the anatomical landmarks.

#### *Step 5: Skeletonisation of uterine artery and ureteric dissection.*

Once the uterine artery was identified, it was skeletonised entirely by dissecting all the fibro-fatty tissue around it using the

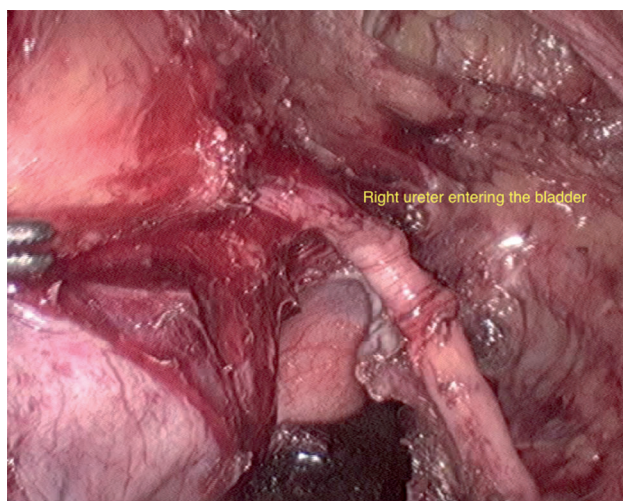


Figure 7. — Ureter is lateralized until its entry into the bladder.

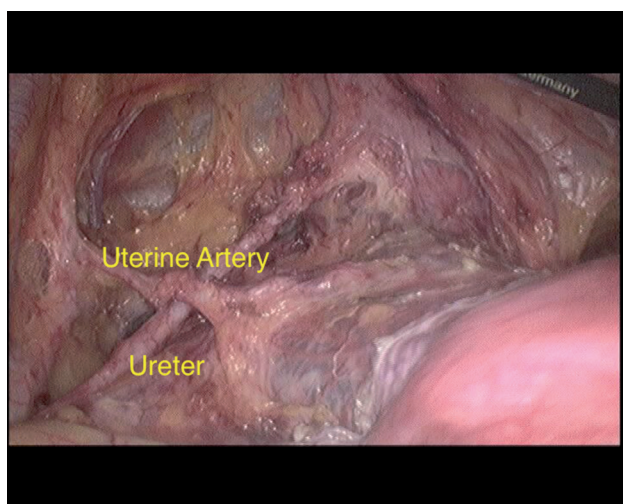


Figure 8. — The relationship of the uterine artery crossing above the ureter.

harmonic shears. Uterine artery was left intact and was mobilized forward and cephalad to aid in the deroofing of the ureteric tunnel. Gentle traction was applied on the uterine artery in the cephalad direction, which exposed the ureter entering the anterior parametrium and facilitated dissection over the medial and superior aspect of the ureter. The ureteric tunnel was developed within the vesicouterine ligament along the superior and medial border of the ureter (Figure 6) using divergent force of the grasper. The vesicouterine ligament contains cervicovesical artery and two of the vesical veins draining into the deep uterine vein. This vasculature was coagulated and cut carefully using harmonic shears. The rest of the avascular connective tissue was dissected away, and ureter was lateralized until its entry into the bladder (Figure 7). Similar steps were performed on the opposite side. The uniqueness of this technique lies in the manipulation of an intact uterine artery in a manner which not only clearly delineates the course of the ureter but most importantly facilitates the deroofing of the ureter with ease.

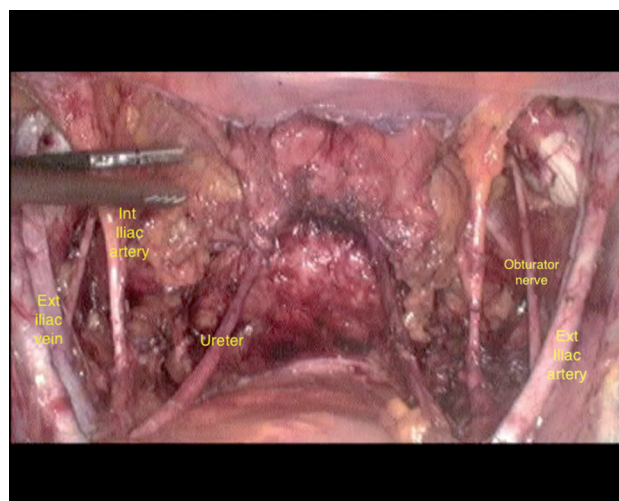


Figure 9. — Final panoramic endoview.

#### *Step 6: Transection of infundibulopelvic ligament or utero-ovarian ligament*

The infundibulopelvic ligament was now coagulated and cut using harmonic shears. In younger patients where ovaries need to be preserved, the utero-ovarian ligament is coagulated and divided using harmonic shears.

#### *Step 7: Uterine artery transected at the origin*

The uterine artery that had been completely skeletonised and separated from the ureter was now coagulated and cut at the origin using harmonic shears on both sides. In the authors' technique the transection of the uterine artery was performed at the end when all the dissection was completed. The relationship of the uterine artery crossing above the ureter is visualized in Figure 8.

#### *Step 8: Transection of the parametrium, paracolpus, and colpotomy*

The uterosacral ligament and the parametrial tissues were transected above the inferior hypogastric nerve for nerve-sparing surgery and below the pelvic splanchnic nerves for non-nerve sparing technique. Parametrium, paracervical, and paracolpus tissues were transected gradually with harmonic shears. Vaginal fornices were reached. Harmonic shears were then used to cut open the fornix from the left lateral aspect. Adequate length of the vaginal cuff was resected circumferentially using the harmonic shears.

#### *Step 9: Retrieval of specimen*

The specimen was placed in the endobag. The edges of the bag were held with the grasper and directed towards vaginal opening. The vaginal assistant grasped the edges of the bag and retrieved the specimen vaginally. This helped to avoid spillage and maintains oncological principles. A vaginal pipe (closed at exterior end) was then introduced, which helped to maintain pneumoperitoneum.

#### *Step 10: Pelvic lymph node dissection*

The authors perform lymph node dissection at the end of radical hysterectomy as the availability of space aided in the dissection of the nodes. Nodes were caught by the grasper, and the lymphatic tissues were removed using harmonic shears. The as-



sistant from right side helped to maintain traction on the peritoneum. The loose areolar and the fibro-fatty tissue along the external iliac artery were swept up to the circumflex iliac vein, which was the caudal limit of the dissection. Remaining parallel to the external iliac artery, the authors skeletonised it completely and removed the nodes. Bleeding from vasa-vasora was stopped using bipolar. Similarly, dissection of an internal iliac artery and obturator nerve lymph nodes was performed systematically. The limit of lymph node dissection was formed laterally by genitor-femoral nerve, medially by the internal iliac artery and obliterated hypogastric artery, distally by circumflex iliac vein, and proximally by the common iliac artery. The nodes were placed in the endobag and retrieved vaginally.

#### Step 11: Vaginal cuff closure

The vaginal cuff was closed laparoscopically using Vicryl No. 1 in a continuous fashion from left vaginal angle to the right (non-locking). After completing vaginal suturing, the authors ensured adequate haemostasis, checked the integrity of the ureters, and performed a saline wash to the abdomen and the intra-abdominal part of trocars. Final panoramic endoview is seen in Figure 9.

#### Postoperative management

Oral fluids were begun six hours after surgery, and early mobilization was encouraged. Foleys catheter was left in situ for 15 days in all the patients operated prior to 2015. They were discharged with catheter in situ and were reviewed again after two weeks when the catheter was removed. They were admitted as a day case and were orally hydrated. If patients were unable to pass urine, they were re-catheterized and discharged with a Foley catheter in place, and trial without a catheter (TWOC) was arranged in two weeks' time. Those patients who passed urine, had their post-voiding residual volume measured with ultrasound, if more than 10 mL for three consecutive occasions, then patients were re-catheterized and TWOC was arranged in seven days.

Since 2015, the authors introduced nerve sparing radical hysterectomy; Foley catheter was routinely removed after 24 hours of the surgery in women, who underwent nerve-sparing surgery. If they were unable to pass urine or if the residual volume was above 100 mL, they were re-catheterized and discharged with a Foley catheter in place, and TWOC was arranged in one week. All patients were advised follow up every three months for the first year, every six months in the second year, and annually after that. The follow-up examinations included clinical examination (general and pelvic examination) and cytological analysis from the vaginal vault. Postoperative adjuvant therapy was given to women in cases of lymph node metastasis, parametrial involvement, positive surgical margins, or if they had two or more intermediate risk factors (lymphovascular space involvement, greater than one-third of stromal invasion and tumor size more than 4 cm).

## Results

A total of 53 patients were subjected to LRH between February 2009 and June 2017. Sixteen (30%) patients underwent nerve sparing type C1 radical hysterectomy and 37 (70%) patients non-nerve sparing type C2 radical hysterectomy.

The median age of the patients was 47 (range, 28-70) years, and the median body mass index was 25.7 (range,

Table 1. — Patient's demographics, histology, and stage.

Median age years (range)	47 (28-70)
Median body mass index (range)	25.7 (16-32)
FIGO Stage (2009)	
1 A2	1
1 B1	26
1 B2	26
Histopathologic type	
Squamous	43 (81.1%)
Adenocarcinoma	8 (15.1%)
Others	2 (3.8%)

16-32) kg/m<sup>2</sup> (Table 1). The median operating time was 103 (range, 61-150) minutes. For the initial four years (2009 to 2013), the median operative time was 135 (range, 90-150) minutes and for the latter years (2014 to 2017), the median operative time was 88 (range, 61-105) minutes. The median blood loss was 30 (range, 20-135) mL (Table 2). None of the laparoscopic procedure was converted to laparotomy. The median length of hospital stay was four (range, 2-8) days. Postoperative complications occurred in 18 patients, of which 13 (24.5%) patients suffered from bladder dysfunction. Twelve patients developed urinary retention and one patient developed neurogenic bladder. The bladder was catheterized in these patients until the residual urine was less than 100 mL. The median time of resumption to normal voiding was 28 (range, 15-35) days. The bladder function did not resume to normal even after five weeks of catheter trial in the woman with neurogenic bladder and the patient is on long-term intermittent self-catheterization. One patient developed vesicovaginal fistula, which was treated with the indwelling catheter for six weeks and the fistula healed spontaneously. The same patient had recurrent urinary tract infections, which were treated with antibiotic courses. Three patients developed lymphoedema and one patient developed pulmonary embolism.

The most common histological variant was squamous cell carcinoma diagnosed in 43 (81.1%) patients followed by adenocarcinoma in eight (15.1%) patients. Neuroendocrine and adenosquamous variety was diagnosed in one (1.9%) patient each. Four (15.4%) patients with Stage IB1 and six (23.1%) patients with Stage IB2 had microscopic lymph node metastasis. Fourteen (26%) patients had histopathologically confirmed parametrial involvement, of which 11 had focal infiltration of parametrium. The median number of pelvic lymph nodes harvested was 20 (range, 8-55). The surgical margins were free of disease in all the cases. The median follow-up in this study was 38 (range 0-97) months. Four patients were lost to follow up. The overall survival curves were produced using Kaplan-Meier method (Figure 10), using SPSS statistical software. The estimated three-year overall survival rate was 92.6% in patients in Stage ≤IB1 and 92.3% in Stage >IB1.

Thirty-five (66%) patients underwent postoperative adjuvant therapy in the form of radiotherapy or chemoradia-

Table 2. — Results.

Median operative blood loss (mL)	30 (20-135)
Median duration of operation (minutes)	103 (61-150)
Median length of hospital stay (days)	4 (2-8)
Conversion to laparotomy	0
Median number of pelvic lymph nodes	20 (8-55)
Positive lymph nodes	18.8%
Parametrial involvement	26%
Positive surgical margins	0
Follow up in months	38 (0-97)
<i>Estimated overall three-year survival rate</i>	
Stage 1B1	92.6%
Stage >1B1	92.3%

tion. There were four (7.5%) deaths in this study, of which one of the patients had a high-grade neuroendocrine tumor with extensive infiltration of parametria and positive pelvic lymph nodes. She received adjuvant chemoradiation as indicated, however, developed brain metastasis. She declined palliative chemotherapy, and died within six months. Second patient died of massive pulmonary embolism on 7<sup>th</sup> postoperative day. The third patient died of renal failure after 30 months of surgery, and the fourth patient also died of renal failure 24 months after the surgery. Recurrence was seen in three patients. One patient had local vault recurrence and the other two patients had distant metastasis (brain and right iliac fossa).

## Discussion

The rationale behind the development of the authors' technique was to have a structured methodology for dissection that exposes the anatomical references necessary for the total LRH to make it safer, with minimal complications. Different authors have used and described different techniques of LRH in the literature. Malzoni *et al.* [7] begin with transection of round ligament, open the paravesical and pararectal space, followed by pelvic lymphadenectomy, and then proceed with radical hysterectomy. Puntambekar *et al.* [8] commence with bladder dissection, followed by dissection of rectovaginal and pararectal space, ureteric tunnel dissection, and completion of radical hysterectomy with pelvic lymph node dissection. Yang *et al.* [9] begin with the dissection of posterior leaf of the broad ligament, and transection of infundibulopelvic and round ligaments. Uterine artery is then coagulated and cut at the origin, followed by dissection of a ureter and pararectal space, and completion of radical hysterectomy with pelvic node dissection.

Although the steps of the surgery remain the same, the sequence of the steps differs with different surgeons. To perform radical hysterectomy safely and efficiently, the six potential spaces should be developed early intraoperatively [10]. The present authors attempted to standardize these steps sequentially to make LRH simple and safe. They propose bladder dissection to be the first step in the technique.

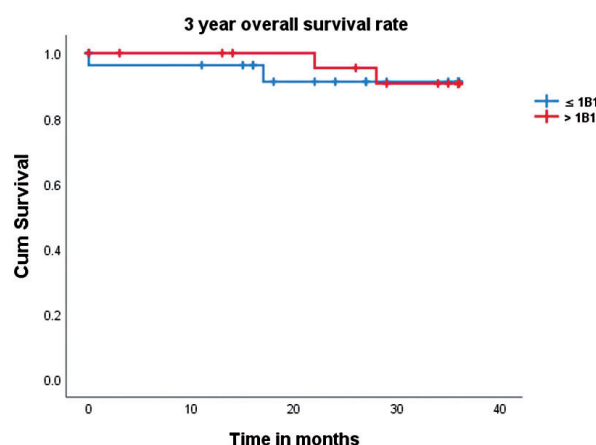


Figure 10. — Kaplan Meier overall survival curves in cervical cancer patients who underwent laparoscopic radical hysterectomy. ( $\leq 1B1$ ,  $n=27$  and  $> 1B1$ ,  $n=26$ ).

The rationale being, that if the bladder is involved during the procedure, the disease stage is upgraded peri-operatively and surgery is abandoned. It is also relatively simple to begin the surgery with bladder dissection. This is followed by dissection of all the six avascular spaces, which help to delineate the anatomical landmarks before embarking upon radical hysterectomy. This would allow adequate excision of the vaginal margins and the specimen to achieve disease-free margins. In all the techniques described in the literature, the uterine artery is cut at its origin, and the cut end is held to help dissect the ureter. In the present authors' experience, the drawback of this technique is that the cut end of the uterine artery obscures the view of the ureteric tunnel during the ureteric dissection. One major difference in the present authors' technique is that the uterine artery is kept intact until the end of the ureteric tunnel dissection and deroofting. Intact uterine artery is manipulated in a specific way to facilitate the ureteric dissection. Another advantage of keeping uterine artery intact until later, is that it helps maintain a good view during ureteric tunnel dissection and deroofting because hemorrhage during coagulation and division of the uterine artery, even if minimal, can obscure laparoscopic vision during dissection. After performing radical hysterectomy, a lymphadenectomy is performed, as there is adequate retroperitoneal pelvic dissection.

The studies on total LRH (Table 3) report intraoperative complication rates ranging from 2.0% to 13.2%, with a conversion rate of 0% to 10.5% [9]. There have been few studies in the literature [2, 11-13] reporting no intraoperative complications associated with LRH in patients with cervical cancer, however in all these studies the number of patients were less than 20 and the stage of cervical cancer was  $\leq 1B1$ . The large study of 404 patients of Yang *et al.* [9] reported an intraoperative complication rate of 1.75%. In

Table 3. — Comparison with other series.

Author	Number of cases (mean, min)	Operative time (median or mean, mL)	Blood loss (median or mean)	Lymph node yield (median mean, days)	Hospital stay [median or No (%)]	Intraoperative complications [No (%)]	Postoperative complications
Nehzat <i>et al.</i> [2]	10	253	300	18.3	3.2	None	None
Kim and Moon [13]	18	363	619	22	12	None	11 (61)
Spirtos <i>et al.</i> [20]	78	205	250	23.8	2.9	9 (11.5)	7 (8.9)
Lin [11]	10	159	250	16.8	4.1	0	0
Gil-Moreno <i>et al.</i> [12]	27	285	400	19.1	5	0	7 (26)
Puntambekar <i>et al.</i> [8]	248	88	200	20.4	3.4	15 (6)	17 (6.8)
Yang <i>et al.</i> [9]	400	240	300	23.5	n/a	7 (1.75)	183 (46)
Malzoni <i>et al.</i> [21]	77	186	57	23	4	n/a	n/a
Pellegrino <i>et al.</i> [15]	107	305	200	26	4	2 (1.9)	21 (20)
Chen <i>et al.</i> [22]	295	162	230	22	10.3	12 (4.1)	139 (47)
Yan <i>et al.</i> [17]	240	264	255	23	n/a	17 (7.08)	22 (9.16)
Present study	53	103	30	20	4	0	18 (34)

comparison, the present study had no intraoperative complication. The authors feel this could be due to two main factors: firstly, in the present authors' technique they first open all the six avascular spaces, as this helps to identify the anatomical landmarks clearly in the pelvis and allows safe and radical dissection. Secondly, they feel that this technique makes ureteric dissection simple by maintaining the uterine artery intact until the end, as it facilitates ureteric tunnel dissection and reduces the risk of injury to the ureter. However, this sample size is small (53) compared to other studies published in literature. The median blood loss in this series was 30 (range, 20-135) mL and none of the patient's required postoperative blood transfusion. To the best of the authors' knowledge, the median blood loss in this study is by far the least amount published in the literature [7, 8, 14-16]. This was due to the excellent magnified vision via latest optical systems and the dual combination of harmonic scalpel and the bipolar graspers, enabling careful haemostasis of the operative field. In addition to the above, knowledge of the vascular anatomy along with the systematic sequence of steps highlighted in this technique further contributed to minimizing blood loss during the surgery. The duration of the procedure varies widely in literature ranging from 88-334.8 minutes [8, 9, 12, 13, 17]. In this study, the median operating time was 103 (range, 61-150) minutes, which is the second shortest operating time in the literature after Puntambekar *et al.* [8]. One of the other observations in this study was that over the years there was a considerable reduction in the operative time due to replication and increased surgical experience.

The retrieval of a total number of 20 pelvic lymph nodes is considered the gold standard for an adequate and complete lymphadenectomy [18]. The median number of lymph nodes harvested in this study was 20, which is comparable to other series [9, 15, 19, 20]. In this study all the patients had disease-free margins that ensured the radicality of the technique. The median length of stay in this study was (range, 2-8) four days, which is comparable to other series in the literature [7, 8, 15]. For the 53 patients included in

this series, four patients were lost to follow up. The estimated three-year overall survival rate was 92.6% in patients in Stage  $\leq$  IB1 and 92.3% in those in Stage  $>$  IB1. Yang *et al.* [9] reported an estimated three-year overall survival rate of 94.9% for the women with a tumor in Stage  $\leq$  IB1, and 81.3% in those with a tumor in Stage  $>$  IB1. The present study had few limitations. It was a retrospective study with a relatively small sample size. The single surgeon with the same team performed all the surgeries and the authors had four patients lost to follow up.

## Conclusion

The present authors' technique of LRH, developed over the years is safe, feasible, and associated with less morbidity. It begins with bladder dissection, which assesses the feasibility of the surgery, followed by dissection of the six avascular spaces, which help to delineate the anatomical landmarks before radical hysterectomy. Intact uterine artery until the end aids in manipulation and dissection of the ureteric tunnel. This technique is associated with low intraoperative complications, minimal blood loss, shorter operative time, and outcomes comparable to other studies. Clear surgical margins and adequate resection of pelvic lymph nodes in all patients indicate that this technique is effective in managing cervical cancer in women up to Stage IB2. This technique also consists of simple steps, which are reproducible and replicable with continuous practice, once the learning curve has been surpassed.

## References

- [1] Canis M., Mage G., Wattiez A., Pouly J.L., Manhes H., Bruhat M.A.: "Does endoscopic surgery have a role in radical surgery of cancer of the cervix uteri". *J. Gynecol. Obstet. Biol. Reprod.*, 1990, 19, 921.
- [2] Nezhat C.R., Burrell M.O., Nezhat F.R., Benigno B.B., Welander C.E.: "Laparoscopic radical hysterectomy with paraaortic and pelvic node dissection". *Am. J. Obstet. Gynecol.*, 1992, 166, 864.
- [3] Salicrú S.R., de la Torre J.F., Gil-Moreno A.: "The surgical management of early-stage cervical cancer". *Curr. Opin. Obstet. Gynecol.*, 2013, 25, 312.

- [4] Hong J.H., Choi J.S., Lee J.H., Eom J.M., Ko J.H., Bea J.W., Park J.H.: "Can laparoscopic radical hysterectomy be a standard surgical modality in stage IA2- IIA cervical cancer?" *Gynecol. Oncol.*, 2012, 127, 102.
- [5] Yan X., Li G., Shang H., Wang G., Chen L., Han Y.: "Complications of laparoscopic radical hysterectomy and pelvic lymphadenectomy— experience of 117 patients". *Int. J. Gynecol. Cancer*, 2009, 19, 963.
- [6] Querleu D., Morrow C.P.: "Classification of radical hysterectomy". *Lancet Oncol.*, 2008, 9, 297.
- [7] Malzoni M., Tinelli R., Cosentino F., Perone C., Vicario V.: "Feasibility, morbidity, and safety of total laparoscopic radical hysterectomy with lymphadenectomy: our experience". *J. Minim. Invasive Gynecol.*, 2007, 14, 584.
- [8] Puntambekar S.P., Palep R.J., Puntambekar S.S., Wagh G.N., Patil A.M., Nayate N.V., Agrawal G.A.: "Laparoscopic total radical hysterectomy by the Pune technique: our experience of 248 cases". *J. Minim. Invasive Gynecol.*, 2007, 14, 682.
- [9] Yang L., Cai J., Dong W., Shen Y., Xiong Z., Wang H., et al.: "Laparoscopic radical hysterectomy and pelvic lymphadenectomy can be routinely used for treatment of early-stage cervical cancer: a single-institute experience with 404 patients". *J. Minim. Invasive Gynecol.*, 2015, 22, 199.
- [10] Bristow R.E.: "Section II: Gynecologic Oncology: Radical abdominal hysterectomy". In: Cundiff G.W., Azziz R., Bristow R.E. *Te Linde's Atlas of Gynaecologic Surgery*. Philadelphia: Wolters Kluwer/Lippincott Williams & Wilkins, 2013, 79.
- [11] Lin Y.S.: "Preliminary results of laparoscopic modified radical hysterectomy in early invasive cervical cancer". *J. Am. Assoc. Gynecol.*, 2003, 10, 80.
- [12] Gil-Moreno A., Puig O., Perez-Benavente M.A., Diaz B., Verges R., De la Torre J., et al.: "Total laparoscopic radical hysterectomy (type II-III) with pelvic lymphadenectomy in early invasive cervical cancer". *J. Minim. Invasive Gynecol.*, 2005, 12, 113.
- [13] Kim D.H., Moon, J.S.: "Laparoscopic radical hysterectomy with pelvic lymphadenectomy for early, invasive cervical carcinoma". *J. Am. Assoc. Gynecol. Laparosc.*, 1998, 5, 411.
- [14] Yan X., Li G., Shang H., Lin F., Yang X., Zheng F.: "Outcome and prognostic factors of laparoscopic radical hysterectomy and pelvic lymphadenectomy in 148 patients with stage IB1 cervical cancer". *Int. J. Gynecol. Cancer*, 2012, 22, 286.
- [15] Pellegrino A., Vizza E., Fruscio R., Villa A., Corrado G., Villa M., et al.: "Total laparoscopic radical hysterectomy and pelvic lymphadenectomy in patients with Ib1 stage cervical cancer: analysis of surgical and oncological outcome". *Eur. J. Surg. Oncol.*, 2009, 35, 98.
- [16] Pareja R., Nick A.M., Schmeler K.M., Frumovitz M., Soliman P.T., Buitrago C.A., et al.: "Quality of laparoscopic radical hysterectomy in developing countries: A comparison of surgical and oncologic outcomes between a comprehensive cancer center in the United States and a cancer center in Colombia". *Gynecol. Oncol.*, 2012, 125, 326.
- [17] Yan X., Li G., Shang H., Wang G., Han Y., Lin T., Zheng F.: "Twelve-year experience with laparoscopic radical hysterectomy and pelvic lymphadenectomy in cervical cancer". *Gynecol. Oncol.*, 2011, 120, 362.
- [18] Panici P.B., Scambia G., Baiocchi G., Greggi S., Mancuso S.: "Technique and feasibility of radical para-aortic and pelvic lymphadenectomy for gynaecologic malignancies: a prospective study". *Int. J. Gynecol. Cancer*, 1991, 1, 133.
- [19] Li, G., Yan, X., Shang, H., Wang G., Chen L., Han Y.: "A comparison of laparoscopic radical hysterectomy and pelvic lymphadenectomy and laparotomy in the treatment of Ib-IIa cervical cancer". *Gynecol. Oncol.*, 2007, 105, 176.
- [20] Spirtos N.M., Eisenkop S.M., Schlaerth J.B., Ballon, S.C.: "Laparoscopic radical hysterectomy (type III) with aortic and pelvic lymphadenectomy in patients with stage I cervical cancer: surgical morbidity and intermediate follow-up". *Am. J. Obstet. Gynecol.*, 2002, 187, 340.
- [21] Malzoni M., Tinelli R., Cosentino F., Perone C., Luzzolino D., Rasile M., Tinelli A.: "Laparoscopic radical hysterectomy with lymphadenectomy in patients with early cervical cancer: our instruments and technique". *Surg. Oncol.*, 2009, 18, 289.
- [22] Chen Y., Xu H., Li Y., Wang D., Li J., Yuan J., Liang Z.: "The outcome of laparoscopic radical hysterectomy and lymphadenectomy for cervical cancer: a prospective analysis of 295 patients". *Ann. Surg. Oncol.*, 2008, 15, 2847.

Corresponding Author:  
D. LIMBACHIYA, M.D., DGO  
Advanced Endoscopy and Oncology Centre  
EVA Women Hospital, Neelkanth Park 2  
Ghoda Camp Road, Shahibaugh  
Ahmedabad, Gujarat 380004 (India)  
e-mail: drdipaklimbachya@gmail.com